

Ultrafast Non-Contrast Enhanced 4D Dynamic MRA with 3D Stack-of-Stars Golden Angle Radial Acquisition and KWIC Reconstruction

Robert X Smith¹, Lirong Yan¹, Stanislas Rapacchi², Yiqun Xue³, Subashini Srinivasan², Daniel Ennis², Peng Hu², Hee Kwon Song³, and Danny JJ Wang^{1,2}
¹Neurology, UCLA, Los Angeles, CA, United States, ²Radiology, UCLA, Los Angeles, CA, United States, ³Radiology, University of Pennsylvania, Philadelphia, PA, United States

Target Audience: Engineers and scientists in the field of MRA

Introduction: The detection and diagnosis of cerebrovascular diseases with MR angiography (MRA) benefits from high spatial resolution for depicting the vascular architecture, as well as high temporal resolution for visualizing the dynamic blood flow pattern. Recently, a novel time-resolved non-contrast enhanced dynamic MRA (dMRA) technique (1,2) was introduced by combining arterial spin labeling (ASL) with a multi-phase segmented TrueFISP readout. However, it remains challenging in existing dMRA methods to achieve an adequate number of slices and temporal phases with both high spatial (e.g., $1 \times 1 \times 1 \text{mm}^3$) and temporal (50-100ms) resolution. Dynamic radial acquisition with a golden angle view increment (3) is a novel technique that is ideally suited for 4D dMRA, given its high degree of efficiency and flexibility for retrospective dynamic image reconstruction. In the present work, we present an ultrafast 4D dMRA technique by employing a 3D stack-of-stars golden-angle radial acquisition in conjunction with temporal filtering strategies (k-space weighted image contrast or KWIC (4)) to achieve 4D dMRA with high spatial and temporal resolution, adequate SNR, and high temporal fidelity.

Methods: The pulse sequence consisted of continuous 3D TrueFISP readout following slice-selective or non-selective inversion pulses. A dynamic 3D radial stack-of-stars sampling with an in-plane view angle increment of $\theta_g=111.25^\circ$ (golden angle) (3) was utilized. 3D radial stack-of-stars sampling was achieved by multiple shots where each shot represented a slice-encoding step. Imaging parameters were as follows: FOV=256mm, 500 views/shot, TR=4.58ms, TE=TR/2, FA=30°, matrix=256x256, 32x1.5mm slices covering a significant portion of the brain, including the Circle of Willis and main branches, scan time = 3 min. Each temporal frame was reconstructed using 160 total views, with an effective temporal resolution of 100 ms (20-view window) via the KWIC filter (4). KWIC exploits the oversampling of the k-space center by encoding drastically fewer views in central region of k-space (20 in this study). This reduction precipitates a proportionately large increase in temporal resolution since image contrast is determined primarily by the signal at k-space center. The number of encoded views is systematically increased during the image reconstruction for more distant regions of k-space. A 3D-Cartesian version of the sequence with closely matched imaging parameters was also assessed for comparison. Thirty phases with a temporal resolution of 80ms covering a 3D slab of 32x1.5mm sections (rate-2 GRAPPA) were acquired within a total scan time of 10 min.

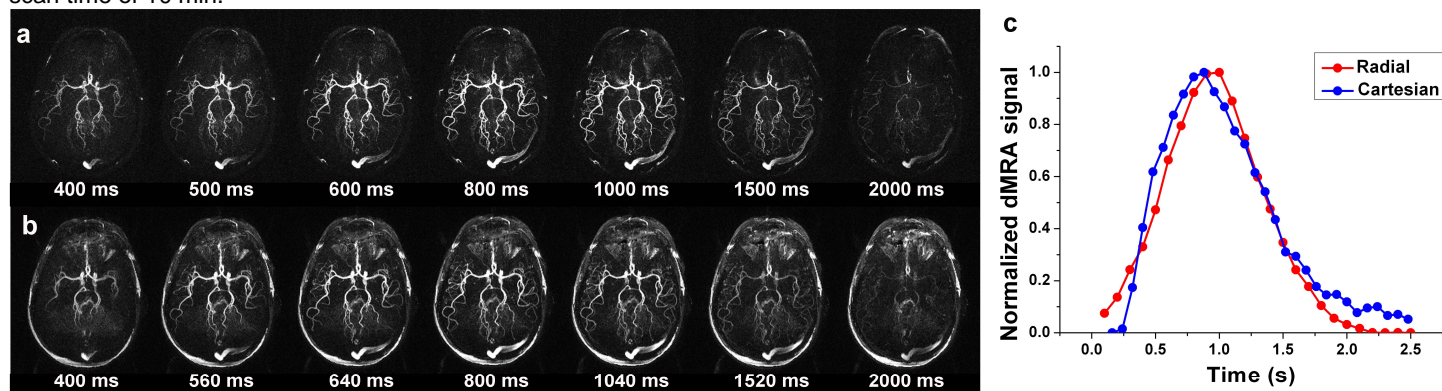


Fig. 1 Representative temporal phases of radial (a) and Cartesian (b) dMRA axial MIP images, and mean time courses of MCA (c).

Results and Discussion: Figure 1 shows dMRA maximum intensity projection (MIP) images acquired at 7 phases using 3D-radial and Cartesian acquisitions. The dynamic blood flow pattern through the Circle of Willis and its main branches can be clearly visualized by radial dMRA, including small distal branches of the middle cerebral artery (MCA) and posterior cerebral artery (PCA). Compared to Cartesian dMRA, the background tissue signal was markedly suppressed in radial dMRA, resulting in sharp MRA images throughout the temporal phases. The contrast-to-noise ratio (CNR) between radial (CNR=9.6) and Cartesian (CNR=11.7) dMRA were comparable, although the scan time of radial dMRA was less than one third of that of Cartesian dMRA. The mean dMRA time course in the MCA is shown in Fig 1c, demonstrating excellent agreement between radial and Cartesian acquisitions.

Conclusion: This work combines the speed of golden angle radial acquisition and the flexibility of KWIC with 3D stack-of-stars TrueFISP acquisitions in 4D dMRA, to dramatically reduce the scan time compared to conventional methods, while maintaining a high spatial and temporal resolution.

Acknowledgments: NIH P41-RR02305; R01-MH080892, R01-NS081077

References (1) Yan et al Radiology 2010, 256:270-9; (2) Bi et al MRM 2010, 63:835-41; (3) Winkelmann et al IEEE TMI 2007, 26: 68-75; (4) Song et al MRM 2004, 52:815-824.